

Research Journal of Pharmaceutical, Biological and Chemical Sciences

Influence of the Immunostimulator «Treatment-and-Prophylactic Immunoglobulin» on the Veterinary and Sanitary Assessment of Meat and the Histologic Picture of Parenchymatous Bodies of Cattle.

Smolentsev Sergey Yurievich^{1*}, Papyndi Ellada Konstantinovna², Volkov Ali Harisovich², Yusupova Galiya Rasihovna², Yakupova Laysan Faizullova³, Korosteleva Valentina Pavlovna³ and Matveeva Elena Lavrentevna⁴.

¹Mari State University, Russia, 424000, Yoshkar-Ola city, Lenin Square 1

²Kazan Bauman state academy of Veterinary medicine, Russia, 420029, Kazan, Sybirsky Tract Street, 35

³Kazan cooperative institute (branch) Russian university of cooperation, Russia, 420081, Kazan city, Ershova str, 58.

⁴Institute of economics, management and law, Russia, 420111, Kazan city, Moscow str., 42

ABSTRACT

At the present stage of development of dairy cattle breeding the main objective of biological science consists in finding rational ways of an extinction or neutralization of action of adverse technogenic and ecological factors. The organism is especially sensitive to influences of adverse factors of environment. The veterinary pharmaceutical market offers the big range of the preparations capable to stimulate protective forces of an organism and to increase resilience to adverse factors. One of such preparations is «Treatment-and-prophylactic immunoglobulin» the let-out Federal State Budgetary Institution Federal Center Toxicological, Radiation and Biological Safety (Russia, Kazan). The purpose of these researches was studying of influence of an immunostimulator "Treatment-and-prophylactic immunoglobulin" on a veterinary and sanitary assessment of meat and a histologic picture of parenchymatous bodies of cattle. Researches were conducted on a farm on sagination of cattle in SHA "Spark" of Kuzhnersky district of the Republic of Mari El where two groups of bull-calves of black and motley breed with a live weight of 420 kg of 5 animals in each group have been created. An animal of the first groups have intramuscularly injected the drug "Treatment-and-prophylactic Immunoglobulin" in a dose of 20 ml with an interval of 48 hours twice. Animals of the second of groups served as control and contained on a usual diet. In 30 days after the beginning of experiment carried out a face of animals up to 3 heads from each group. For a veterinary and sanitary assessment took 2 samples of meat from muscles of sgibatel and razgibatel of chest and pelvic extremities of hulk 10 centimeters long. In meat defined pH, the content of aminoammoniac nitrogen, zinc, copper, iron, cobalt, selenium, magnesium, lead, cadmium, mercury, arsenic. Carried out reaction to peroxidase and with sulfate copper for definition of freshness of meat. For histologic researches took 3 samples of 2x4 cm in size from a liver, kidneys, a myocardium, lymph nodes and a spleen. Pathological material was placed in a vessel with 10% water solution of formalin. Then pieces of fabric filled in with paraffin with a temperature of 55 °C and left for 2 hours. After that by means of the microtome made histologic cuts 5-7 microns thick and painted hematoxylin-eozinom. Researches of structure of fabrics and cages of bodies carried out by means of a microscope of "Leica DM 1000". Photography was carried out on the Nikon coolpix 4500 digital camera. Researches have shown that pH meat of skilled group I made 5,32±0,03, and in control - 5,43±0,02, the level of aminoammoniac nitrogen – 1,19±0,02 and 1,21±0,01 mg respectively in skilled and control groups. Reaction to peroxidase both in skilled, and in control groups was positive, and reaction with sulfate copper – negative. content of copper was above control for 34% (1,80±0,03 mg/kg). Concentration of zinc has made 38,5±1,32 and 23,1±0,98 mg/kg respectively in skilled and control groups. Iron levels, both in skilled, and in control groups were similar among themselves. Content of cobalt in meat of bull-calves was above an indicator of control group for 24,6%. Concentration of selenium and magnesium in meat of bull-calves of skilled group was higher in comparison with control. Such heavy metals as lead, cadmium, mercury, and arsenic in meat of skilled and control groups haven't been found. By results of histologic researches it is established that this preparation doesn't cause pathological changes in a structure of a liver, kidneys, a myocardium, lymph nodes and a spleen.

Keywords: cattle; examination; meat assessment; quality; immunostimulator; histologic researches; parenchymatous bodies.

**Corresponding author*

INTRODUCTION

Transfer of animal husbandry to industrial technology which feature is new methods of contents of feeding and operation, and the increase in concentration of a livestock, potentially pathogenic microorganisms connected with it in rooms, change of their initial properties, influence on an organism of animals technological a stress factors, the ecological trouble of external environment which is aggravated with almost universal deficiency in sterns of minerals sets for veterinary experts new complex challenges of health protection of animals [1;2;3].

Influence of these factors influences adaptive and adaptable mechanisms at animals, changing them that leads to decrease in nonspecific resistance and immunity or increase of reactivity [4;5].

Emergence of violations of functions of immune system is one of pathogenetic mechanisms of any pathological process [6;7].

Now the assessment of the immune status of animals depending on age, a physiological state, influence of the pathogenic factors causing developing of diseases, and a possibility of his correction by the preparations possessing antioxidant and indirectly immunomodulatory action [8] is actual.

In foreign countries apply immunostimulators at treatment sharp infectious and oncological diseases [9;10].

One of the new preparations possessing the immunostimulating action is «Treatment-and-prophylactic immunoglobulin» the let-out Federal State Budgetary Institution Federal Center Toxicological, Radiation and Biological Safety (Russia, Kazan).

This preparation is received from serum of blood of horses, and represents immunological the active proteinaceous fraction containing mainly the class G immunoglobulins possessing the increased biological activity due to ability to occlude native molecules of immunoglobulins, enzymes, hormones and other proteins promotes increase of bactericidal activity and plays a significant role in antiviral immunity.

The purpose of researches – to study influence of an immunostimulator "Treatment-and-prophylactic immunoglobulin" on a veterinary and sanitary assessment of meat and a histologic picture of parenchymatous bodies of cattle.

MATERIALS AND METHODS

Researches have been conducted on a farm on sagination of cattle in SHA «Spark» of Kuzhenersky district of the Republic of Mari El. Two groups of bull-calves of black and motley breed with a live weight of 420 kg of 5 animals in each group have been created. An animal of the first groups have intramuscularly injected the drug «Treatment-and-prophylactic Immunoglobulin» in a dose of 20 ml with an interval of 48 hours twice. Animals of the second of groups served as control and contained on a usual diet.

In 30 days after the beginning of experiment carried out a face of animals up to 3 heads from each group. For a veterinary and sanitary assessment took 2 samples of meat from muscles of sgibatel and razgibatel of chest and pelvic extremities of hulk 10 centimeters long. Each sample of meat was wrapped separately in a polyethylene film.

In meat defined pH, the content of aminoammoniac nitrogen, zinc, copper, iron, cobalt, selenium, magnesium, lead, cadmium, mercury, arsenic. Carried out reaction to peroxidase and with sulfate copper for definition of freshness of meat.

For histologic researches took 3 samples of 2x4 cm in size from a liver, kidneys, a myocardium, lymph nodes and a spleen. Pathological material was placed in a vessel with 10% water solution of formalin. Then pieces of fabric filled in with paraffin with a temperature of 55 ° C and left for 2 hours. After that by means of the microtome made histologic cuts 5-7 microns thick and painted hematoxylin-eosinom.

Researches of structure of fabrics and cages of bodies carried out by means of a microscope of «Leica DM 1000». Photography was carried out on the Nikon coolpix 4500 digital camera.

RESULTS OF RESEARCHES

Organoleptic researches have shown that meat of control and skilled groups of animals had a dry crust of light pink color. The place of a zarez was uneven, is impregnated with blood more intensively, than in other places of hulk, the consistence - dense, elastic, when pressing by a finger was formed a dimple which was quickly leveled. Muscles on a section were slightly uvklazhnenny, didn't leave a damp spot on filter paper and imekl light-red color. Blood in muscles and in blood vessels was absent, small vessels under a pleura and a peritoneum weren't illuminated. The section surface the limfatikcheskikh of knots was light gray color.

The broth made from meat, - transparent, fragrant, on his pokverkhnost the insignificant congestion of big drops of fat was noted. Taste of broth pleasant, foreign smacks weren't noted.

Sinews were elastic, dense, a surface of joints smooth, brilliant.

In dabs prints from deep muscles in sight of a microscope single cocci and rhabdoid bacteria have been found, Lethal weight in skilled group was 4,3% higher in comparison with control group. A lethal exit made in experience 62,6±2,43%, and in control - 56,8±1,55%.

From data of table 1 it is visible that pH meat of skilled group I made 5,32±0,03, and in control - 5,43±0,02, the level of aminoammoniac nitrogen – 1,19±0,02 and 1,21±0,01 mg respectively in skilled and control groups.

Reaction to peroxidase both in skilled, and in control groups was positive, and reaction with sulfate copper – negative that testified to high quality of meat.

Table 1 - Biochemical indicators of meat of cattle

Indicator	Groups	
	Skilled	Control
pH	5,32±0,03	5,43±0,02
Aminoammoniac nitrogen, mg	1,19±0,02	1,21±0,01
Reaction to peroxidase	+	+
Reaction with sulfate copper	-	-

Table 2 – The maintenance of mineral elements in meat of bull-calves

Indicator	Groups	
	Skilled	Skilled
Copper, mg/kg	1,80±0,03	1,34±0,02
Zinc, mg/kg	38,5±1,32	23,1±0,98
Iron, mg/kg	462,7±12,8	451,1±9,11
Cobalt, mkg / 100	9,51±0,32	7,63±0,26
Selenium, mkg / 100	2,27±0,04	1,41±0,03
Magnesium, mg/kg	170,5±8,21	151,9±5,39
Lead, mg/kg	It isn't found	It isn't found
Cadmium, mg/kg	It isn't found	It isn't found
Mercury, mg/kg	It isn't found	It isn't found
Arsenic, mg/kg	It isn't found	It isn't found

From table 2 it is visible that in skilled group the content of copper was above control for 34% (1,80±0,03 mg/kg). Concentration of zinc has made 38,5±1,32 and 23,1±0,98 mg/kg respectively in skilled and control groups.

Iron levels, both in skilled, and in control groups were similar among themselves. Content of cobalt in meat of bull-calves was above an indicator of control group for 24,6%.

Content of selenium and magnesium in meat of bull-calves of skilled group was higher in comparison with control. Such heavy metals as lead, cadmium, mercury, and arsenic in meat of skilled and control groups haven't been found.

Histologic researches have shown that the cardiac muscle is formed by heart muscular tissue which elements are kardiomiotsita cages. Strom it is presented by layers friable fibrous not properly executed connecting fabric which are expressed poorly.

More dark coloring of lymph nodes (figure 1 and 2) is characteristic of cortical substance, and lighter coloring for brain substance. Cortical substance of knot is formed by roundish follicles which represent round congestions of limfotsikt in retikulyarny fabric. Pulpy tyazh which network forms brain substance depart from cortical substance - it is tape-like congestions of lymphocytes in retikulyarny fabric. On the periphery of a cut the capsule formed by friable connecting fabric with fatty segments is noted.

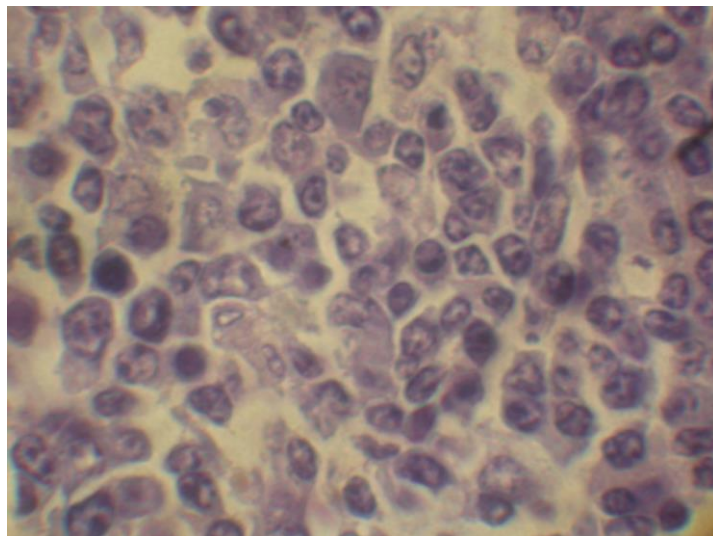


Fig 1 - Lymph node of cattle, peripheral zone, control group, coloring by hematoxylin and eoziny, h1000

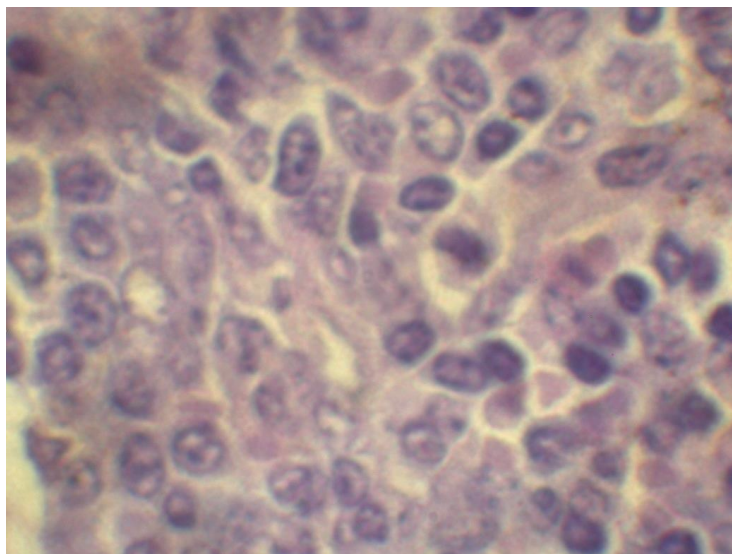


Fig 2 - Lymph node of cattle, peripheral zone, skilled group, coloring by hematoxylin and eoziny, h1000

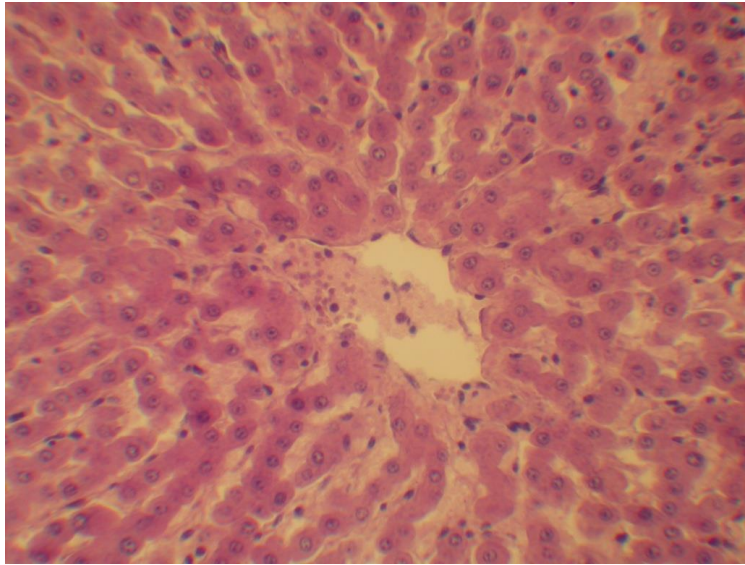


Fig 3 - Liver of cattle, control group, coloring by hematoxylin and eoziny, h210

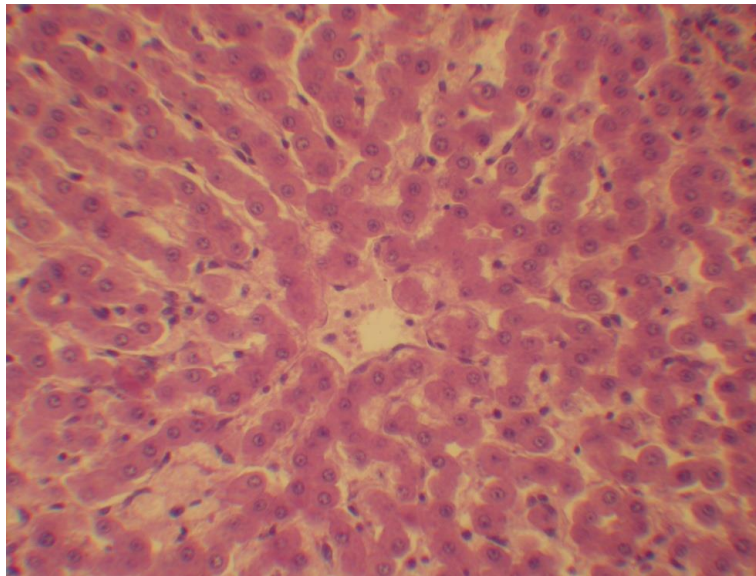


Fig 4 - Liver of cattle, skilled group, coloring by hematoxylin and eoziny, h210

In a liver (figure 3 and 4) the insignificant amount of the connecting fabric dividing segments and the segments which are mainly on the course of vessels at edges is noted. The lobular structure is noticeable by a radial arrangement of plates around the central veins. The wall of the central vein is formed endotelily and a podendotelialny layer of connecting fabric. Radially hepatic plates depart from her. Kernels of hepatocytes round, have various size. The wall the vnutridolkovykh of capillaries is almost not noticeable, but kernels an endoteliya of capillaries are well visible.

Kidneys are covered with a capsule from fibrous connecting fabric. Cortical substance on a preparation is emitted with the tubules cut in the various directions and forming a kidney labyrinth in which kidney balls are noticeable. Kidney tubules throughout are formed by a single-layer epithelium. Brain beams which tubules are cut lengthways press in cortical substance; pass in brain beams mainly tubules of loops, and in deep parts initial departments of collective tubes join them. Brain substance consists of direct tubules of collective tubules.

In a spleen follicles represent spherical congestions of lymphocytes in the retikulyarny fabric forming a spleen basis. In follicles the central arteries are found. The capsule of a spleen is formed by connecting fabric. Trabeculas depart from a capsule. In cuts there are blood vessels; trabekulyarny arteries. All space between a capsule, trabeculas and malpigiyevy little bodies is occupied by the red pulp formed by retikulyarny fabric.

CONCLUSION

Results of researches have shown that pH meat skilled and control groups I made $5,32 \pm 0,03$ and $5,43 \pm 0,02$, the level of aminoammoniac nitrogen – $1,19 \pm 0,02$ and $1,21 \pm 0,01$ mg respectively. Reaction to peroxidase both in skilled, and in control groups was positive, and reaction with sulfate copper – negative. Content of copper of m meat of skilled group was above control for 34% ($1,80 \pm 0,03$ mg/kg). Concentration of zinc has made $38,5 \pm 1,32$ and $23,1 \pm 0,98$ mg/kg respectively in skilled and control groups. Iron levels, both in skilled, and in control groups were similar among themselves. Content of cobalt in meat of bull-calves was above an indicator of control group for 24,6%. Concentration of selenium and magnesium in meat of bull-calves of skilled group was higher in comparison with control. Such heavy metals as lead, cadmium, mercury, and arsenic in meat of skilled and control groups haven't been found out that conforms to requirements for fresh, good-quality meat.

By results of histologic researches it is established that this preparation doesn't cause pathological changes in a structure of a liver, kidneys, a myocardium, lymph nodes and a spleen.

REFERENCES

- [1] Ostrovskij M. Immunitet teljat // Zhivotnovodstvo Rossii.- 2007.-№2.-P.49-50.
- [2] Pogodaev V.A. Ajsanova B.A. Ispol'zovanie kompleksnogo immunomoduljatora v skotovodstve // Zootehnija.-2008.-№ 7.-P.6-7.
- [3] Smolentsev S.Yu., Papunidi E.K., Korosteleva V.P., Matveeva E.L. Yusupova G.R. Prospects for the use of therapeutic and preventive immunoglobulin in veterinary // Research Journal of Pharmaceutical, Biological and Chemical Sciences.-2014.-№5(6).-P.1448-1452.
- [4] Samartsev V.N., Smirnov A.V., Zeldi I.P., Markova O.V., Mokhova E.N., Skulachev V.P. Involvement of aspartate/glutamate antiporter in fatty acid-induced uncoupling of liver mitochondria // Biochimica et Biophysica Acta (BBA)- Bioenergetics.-1997.-T.-1319.-№ 2-3.-C. 251-257.
- [5] Mosrnnann T.R. Two types of murine helper T cell clone. J. Definition according to profiles of lymphokine activities and secreted proteins / T.R. Mosrnnann // Immunology.-2006.-№136.-P.2348—2357.
- [6] Nagaoka I., Tamura H., Hirata M. An antimicrobial cathelicudin peptide, human CAP18/LL37, suppresses neutrophil apoptosis via the activation of formyl-peptide receptor-like 1 and P2X7 // Immunology.-2007.-Vol. 176.-P. 3044-3052.
- [7] Termeer C., Hennies J., Voith U. Oligosaccharides of hyaluronan are potent activators of dendritic cells // Immunol.-2011.-Vol. 165.-P. 1863-1870.
- [8] Waldmann T.A. Immunotherapy: past, present and future // Nat.Med.-№3.-2003.-P.267-277.
- [9] Escrivá L., Font G., Manyes L. *In vivo* toxicity studies of fusariummycotoxins in the last decade: A review // Food and Chemical Toxicology, Volume 78, April 2015, Pages 185-206.
- [10] Raynal M, Bailly J.D., Benard G., Guerre P. Effects of fumonisin B1 present in Fusarium moniliforme culture material on drug metabolising enzyme activities in ducks // Toxicology Letters, Volume 121, Issue 3, 19 May 2001, Pages 179-190.